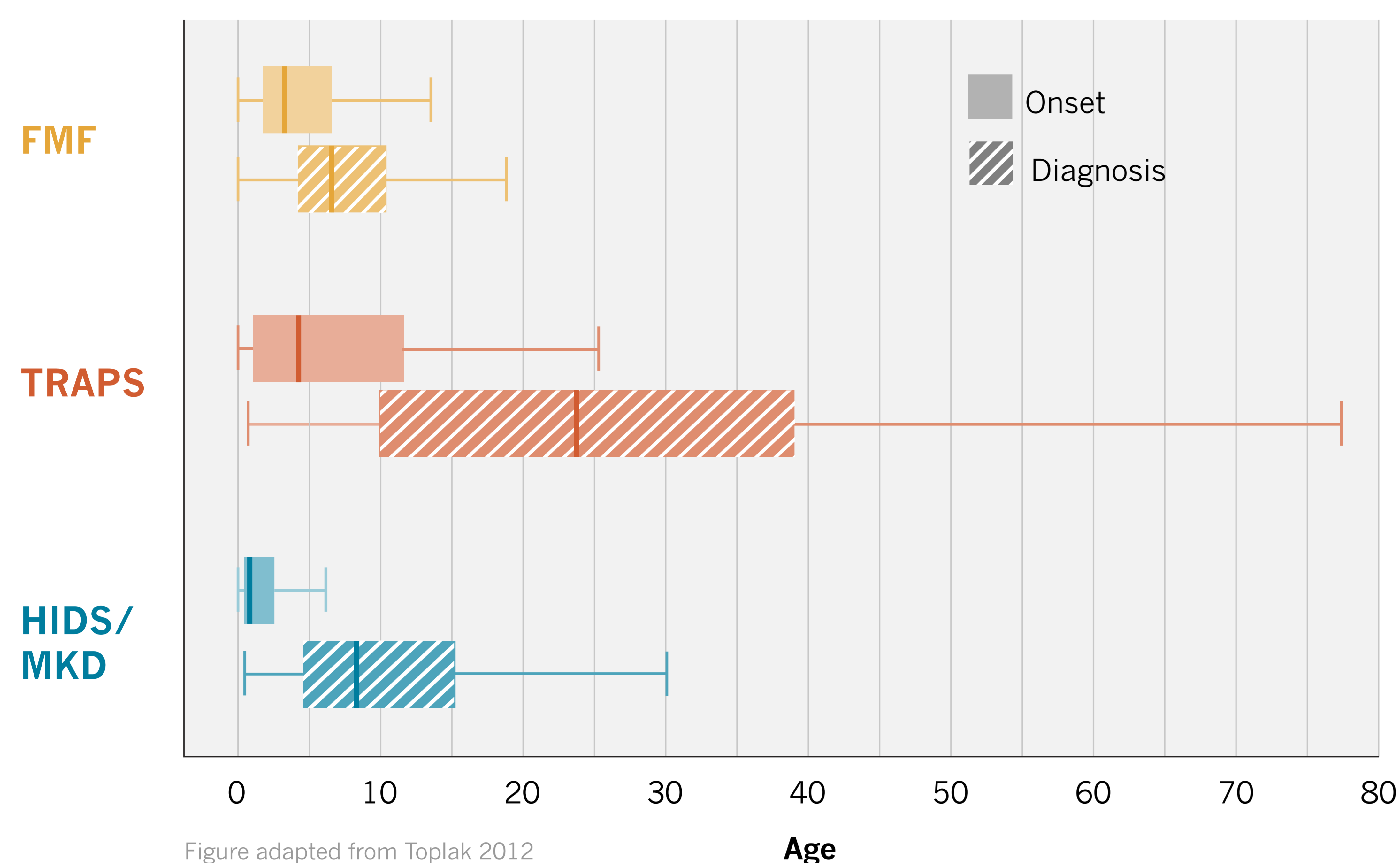


## An Ongoing Challenge for Clinicians

# Diagnosing FMF, TRAPS and HIDS/MKD

## Delayed Diagnoses Are Common



Autoinflammatory diseases often share clinical features, and molecular analyses can be inconclusive in some cases!<sup>2</sup>

Eurofever Registry data from more than 1800 patients in 31 countries show that **patients may wait years for the correct diagnosis** (figure)<sup>1</sup>

These trends were confirmed in a smaller international registry of FMF, TRAPS, and HIDS/MKD patients (n=139), where **time from symptom onset to diagnosis ranged from 3.5 to 12.7 years**.<sup>3</sup>

**Diagnostic challenges may lead to unnecessary medical procedures.** In FMF, for example, abdominal pain during an acute attack may mimic acute appendicitis, a leading cause of hospitalization and surgery.<sup>4</sup>



## Progress in Classification and Management

Provisional classification criteria have been developed to aid in diagnosis of FMF, TRAPS and HIDS/MKD (tables)<sup>2</sup>

In response to inadequate evidence-based guidelines, SHARE has established management and monitoring recommendations to optimize care in children and young adults with TRAPS or HIDS/MKD.<sup>5</sup>

FMF	
Presence	Score
Duration of episodes <2 day	9
Chest pain	13
Abdominal pain	9
Eastern Mediterranean* ethnicity	22
Northern Mediterranean* ethnicity	7
Absence	
Aphthous stomatitis	9
Urticarial rash	15
Enlarged cervical lymph nodes	10
Duration of episodes >6 days	13
<b>Cut-off</b>	<b>≥60</b>

TRAPS	
Presence	Score
Periorbital edema	21
Duration of episodes >6 days	19
Migratory rash†	18
Myalgia	6
Relatives affected	7
Absence	
Vomiting	14
Aphthous stomatitis	15
<b>Cut-off</b>	<b>≥43</b>

HIDS/MKD	
Presence	Score
Age of onset <2 years	10
Aphthous stomatitis	11
Generalized enlargements of lymph nodes or splenomegaly	8
Painful lymph nodes	13
Diarrhea (sometimes/often)	20
Diarrhea (always)	37
Absence	
Chest pain	11
<b>Cut-off</b>	<b>≥42</b>

\*Eastern Mediterranean: Turkish, Armenian, non-Ashkenazi Jewish, Arab. Northern Mediterranean: Italian, Spanish, Greek. †Centrifugal migratory, erythematous patches most typically overlying local area of myalgia, usually on the limbs or trunk.

FMF, Familial Mediterranean fever; SHARE, Single Hub and Access point for paediatric Rheumatology in Europe.

References 1. Toplak N, et al. *Ann Rheum Dis.* 2012;71:1177-82 2. Federici S, et al. *Ann Rheum Dis.* 2015;74:799-805 3. Özen S, et al. *Ann Rheum Dis.* 2014;73(suppl 2):106. 4. Sari I, et al. *Eur J Rheum.* 2014;1:21-33. 5. ter Haar N, et al. *Ann Rheum Dis.* 2015 Jun 24. doi:10.1136/annrheumdis-2015-207546. [Epub ahead of print]